INAUGURAL LECTURE SERIES 290

THAT I MAY SEE ....

By

BERNICE OLUWAKEMI ADEGBEHINGBE

Professor of Ophthalmology (Glaucoma Specialist)

OBAFEMI AWOLOWO UNIVERSITY PRESS, ILE-IFE, NIGERIA.

Bernice Oluwakemi ADEGBEHINGBE
Professor of Ophthalmology (Glaucoma Specialist)

THAT I MAY SEE ....

An Inaugural Lecture Delivered at Oduduwa Hall,
Obafemi Awolowo University, Ile-Ife, Nigeria,
On Tuesday 30th August, 2016

By

Bernice Oluwakemi ADEGBEHINGBE

BSc. Hons(Ife), MBChB, DORCS (Ir.), MSc. Ophth.(Engl.), FWACS, FMCOphth., FICO, FICS

Professor of Ophthalmology (Glaucoma Specialist)

Inaugural Lecture Series 290

ISSN 0189-7848

Printed by

Obafemi Awolowo University Press Limited
Ile-Ife, Nigeria.

PREAMBLE

Mr. Vice Chancellor Sir, Principal Officers of the University, Members of the University Council, Members of the Senate, Provosts, Deans, Directors, Head of Departments, Invited Guests, Gentlemen of the press, distinguished ladies and gentlemen. It is with heartfelt appreciation and immense gratitude to the Almighty God that I stand before you and this genuinely August Assembly today to deliver this Inaugural Lecture being the first ever from the new Department of Ophthalmology of the Obafemi Awolowo University. I am a Professor of Ophthalmology in the College of Health Sciences and the first woman in the College to give an inaugural lecture. I am immensely grateful to the Obafemi Awolowo University for providing me with the platform for academic development from my undergraduate days and for giving me the enabling environment to strive to attain academic excellence to the highest status in academics as a Professor in my chosen field. I am highly humbled to stand here today before this most learned academic community and the public at large, to share my clinical experiences and my academic passion and mission as an Ophthalmologist.

Mr Vice Chancellor Sir, I give honour to all my teachers today who have contributed to molding me into the image of academic excellence which I have been able to attain. I fondly remember my late dad who was the first to drum into my ears his desire for me to become a professor when I was just a teenager. I appreciate my sweet mum who was fond of bombarding me with gifts each time I came first in my college thus encouraging me to aspire and aim higher in my academic pursuits. I give all glory to God for without God, I can do nothing and I am less than nothing but with God I have been able to do all things through Christ who strengthens me.

INTRODUCTION

And he said to him, "What do you want me to do for you?" But he said, "My Lord that I may see." Luke 18:35-43 (Good news Bible). This poor blind man sat by the wayside, begging. He was not only blind, but poor.

"That I may see" was the request of the blind man to our Lord Jesus Christ. This confirms that the problem of blindness and severe visual impairment has been with humankind since time immemorial. There were references to people with blindness in the bible who had other challenges but the most overriding single desire of all of these people was to regain their sight.

Since I qualified as an ophthalmologist and during the course of my career the most common single mantra desire of my patients is: "Doctor, I don't want to go blind". On such occasions, I try to assure them: "you cannot since we are making your diagnosis and giving you appropriate treatment early".

For those who are already blind by the time we see them, the single most important paramount desire from such is that they may regain their sight. The majority of the blinding conditions are preventable or treatable but late diagnosis, misdiagnosis and improper treatment of blinding eye diseases are the most common causes of blindness. Blindness is a disaster and the gift of sight is divine and a blessing of great value from God.

Eyes are very important to all creatures. In the avian world, the eagle's eyes are the sharpest, thus enabling it to see the smallest possible prey from an incredible lofty height. Most animals (and man) have two eyes except for Cyclops Shark (mythology). Life and sight preservation from the "cradle to the grave" is the primary function of the Ophthalmologist" As God gives life and sight in His infinite goodness, ophthalmologist are saddled with the roles of preserving both. There is nothing more disabling than the loss of sight and so the duty of the Ophthalmologist is to assist the patient in sustaining the maximum functions of the eyes.

Mr Vice Chancellor, the eyes that look are common but the eyes that *see* are rare. Many individuals are going about suffering from various degrees of visual impairment and impending blindness without knowing it. Ophthalmologists are in the fore front of the race for preventing visual impairment and blindness. These they do with the support of other members of the eye care team including the Optometrist/ Opticians, Ophthalmic nurses and ophthalmic health assistants.

My quest for research and academic excellence was borne out of my exposure during my MSc programme in Advanced Ophthalmology at the University of Bristol, UK. Working in the glaucoma clinic with Prof David L Easty, I became very interested in glaucoma being the most common cause of irreversible blindness worldwide. My research interest has been epidemiology of eye diseases emphasizing the importance of blindness prevention through early diagnosis and public eye health education.

The World Health Organization (WHO), the International Agency for Blindness Prevention (IAPB) and a consortium of non-governmental organizations (NGOs) launched the Global Initiative for Elimination of Avoidable blindness: VISION 2020 (Right to Sight). My contribution to knowledge has been through good research output, effective teaching and dedicated clinical service. My research work has been mostly clinical with an emphasis on the community approach to blindness prevention, focusing on defining patterns and trends of ophthalmic disorders as encountered in this environment. In our research, we aim to provide the basis for an improvement in contemporary ophthalmic practice in Nigeria and achieve the realization of the objectives of VISION 2020 which is the Elimination of Avoidable Blindness by the year 2020 (giving to all humankind, young and old, the "Right to Sight"). I have worked in collaboration with colleagues in my department, other departments in my faculty and other faculties within the university as well as other universities across the country. To achieve the objectives of VISION 2020, most of my research activities and findings have been focused on community-

based preventive ophthalmology. My main objectives has been focused on the Prevention of Blindness and the Epidemiology of eye disease and issue of Glaucoma in Nigeria.

In conjunction with my other members of the Department of Ophthalmology, I adopted the "Community Approach" to Prevention of Blindness through Primary .Eye Care Model. Primary Eye Care (PEC) is a broad concept, encompassing the prevention of a potentially blinding eye disease through Primary Health Care (PHC). I have been able to coordinate various outreaches in the communities with the aim of preventing or treating avoidable blindness over the past 16 years. We organized community-based programmes that utilize some elements of Primary Eye Care which include:

- community participation
- identification with treatment
- referral of individuals with treatable causes of blindness with colossal socio-economic consequences.

We discovered that the pattern and prevalence of blindness and visual impairment in many communities in Nigeria differ from what obtains in the western countries; the major causes documented were cataract, ocular infections, refractive errors and glaucoma (Adegbehingbe *et al*, 2008). Information gathered during our outreaches, field works and community surveys has contributed significantly to the national blindness prevalence database, especially on major causes of preventable blindness in Nigeria, including glaucoma.

Figure 1: The Lecturer conducting an Eye Health Education talk on Television

Figure 2: Live Interactive Eye Health Talk on a Radio station

It is a known fact that visual impairment can limit people's ability to perform everyday tasks and can affect their quality of life and ability to interact with the surrounding world. Most of the diseases and conditions causing visual impairment and blindness can be prevented or readily treated with known and cost-effective interventions. Good quality rehabilitation allows people with different degrees of visual impairment to fully profit from life,

achieve their goals and be active and productive in their community.

What is blindness?

Literally, if a person is unable to perform a task for which eyesight is essential then he or she is blind.

The World Health Organisation defined blindness as a situation where the best Visual acuity (VA) of someone is less than 3/60 in the better eye with best correction or a visual field less than 10 degrees from fixation. However, in India if the VA < 6/60 with correcting glasses in the better eye in day light, the person is blind. There are 4 levels of visual function, according to the International Classification of Diseases -10 (ICD-10):

- 6/6 - 6/18 -Normal Vision
- 6/18 - 6/60 -Moderate Visual Impairment (MVI)
- 6/60 - 3/60 -Severe Visual impairment (SVI)
- 3/60 - NPL -Blindness

Moderate visual impairment combined with severe visual impairment is grouped under the term *"Low Vision"*. Low vision taken together with blindness represents all visual impairments.

Facts about Blindness/Visual Impairment.

1. As at the year 2010, about 285 million people (globally) were visually impaired, of whom 39 million were blind. Later data put the number of the blind at about 46 million. Also an, estimated 19 million children are visually impaired and more than 5.2 million blind, though majority are treatable. About two-thirds (12 million) of visual impairment in children are due to refractive errors, a condition that could be easily diagnosed and corrected. However, it is estimated that about 1.4 million children are irreversibly blind for the rest of their lives and will need visual rehabilitation

interventions for a full psychological and personal development (Goh PP *et al*, 2005).

2. On the average, one person goes blind every five seconds and one child goes blind every minute. Interestingly, more than 75 percent of all blindness are reversible (cataract) or preventable (Trachoma). Ninety percent of all cases of new blindness occur in the developing world (WHO). In Nigeria alone, over 1 million adults aged 40 years and above are blind while more than 3 million are visually impaired. It was reported that 4.25 million adults aged 40 years in Nigeria are either visually impaired or blind (Rabiu *et al*, 2001).

3. Globally, uncorrected refractive errors are the main causes of moderate and severe visual impairment. Refractive errors (far and near sightedness) are among the simplest to correct cases of visual impairment; almost all of them can be corrected and normal vision can be restored with eyeglasses, contact lenses or refractive surgery. Cataracts remain the leading cause of blindness in the industrialized and developing countries (Steven GA, 2013).

4. According to the World Health Organization an estimated 82% of all people who are blind are over 50years. This number is expected to increase with the world's population aging.

5. Almost 28% of people living with moderate and severe visual impairment are in their working years. Visual limitation has an impact on the ability of working people to conduct a productive life. This seriously affects their ability to find employment and support themselves and provide for their families. Hence blindness is strongly associated with poverty (WHO, 2007).

6. Retinal diseases are the main causes of visual impairment in upper-middle- and high-income countries. Targeting the exposure to risk factors (smoke, genetic pre-disposition, systemic diseases) and performing regular eye examinations

will allow an early diagnosis of the disease, and early treatment to avoid or delay the onset of diminished visual function.

7. Up to 80% of visual impairment and blindness in adults are preventable or treatable. To achieve a substantial reduction, the general public needs to be educated in preventive measures. The health care system needs to include eye care services to achieve universal health coverage. Worldwide the major causes of blindness in children include cataract, retinopathy of prematurity (ROP), and vitamin A deficiency. Approximately half of all childhood blindness can be avoided or treated.

Ten major causes of visual impairment and blindness

Globally, major causes of visual impairment are uncorrected refractive errors (myopia, hyperopia or astigmatism), 43%; unoperated cataract, 33% and glaucoma, 2%; but cataract remains the most common cause of blindness worldwide. Some diseases, such as trachoma and river blindness, are prevalent mostly in less developed areas of the world where there are also specific environmental hazards. However, in many industrialized countries, a few other eye conditions have emerged as potential threats to the status of sight of their populations.

The increase of diabetes among many population groups has caused diabetic retinopathy to be added to the list of leading causes of blindness, also glaucoma blindness has attained a level of epidemiological significance with its associated challenges of difficulties in its early diagnosis and the necessity of life-long treatment. Age-related macular degeneration (AMD) also ranks high among the global causes of visual impairment with a blindness prevalence rate of 8.7%. It is the primary cause of visual deficiency in industrialized countries.

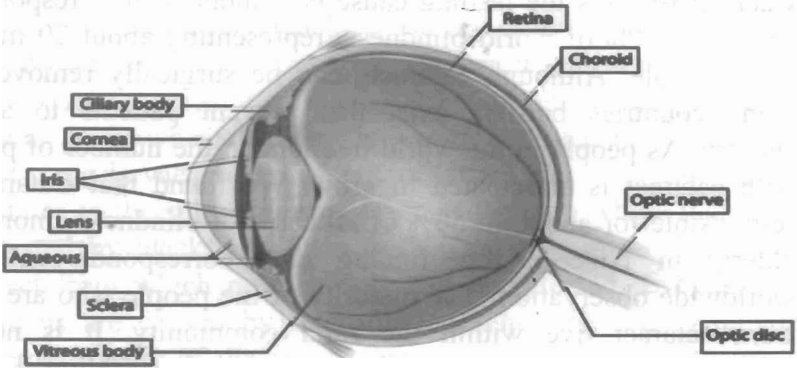

https://www.willseye.org/**anatomy-of-the-eye**

Figure 3: The diagram above depicts the various part of the eye (Anatomy).

Generally speaking, whatever affects any part of the eye could cause visual impairment or blindness.

1. Cataract

Cataract is clouding of the lens of the eye that prevents clear vision. Although most cases of cataract are related to the ageing process, occasionally children can be born with the condition, or a cataract may develop after eye injuries, inflammation, and some other eye diseases.

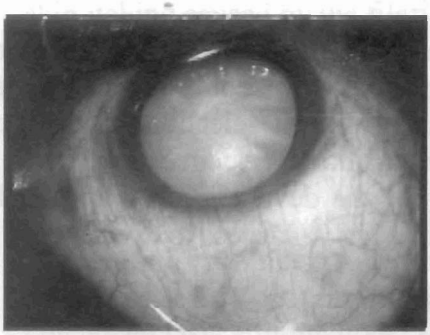

Figure 4: Cataract. This mature cataract is causing blindness. Surgery will restore vision in this eye.Delay can cause the lens to become swollen (Intumescent) leading to glaucoma or intractable iritis (Inflammation within the eye).

https://nei.nih.gov/health/eyediagram

Cataract remains the leading cause of blindness. It is responsible for about 51% of world blindness, representing about 20 million blind people. Although cataracts can be surgically removed, in many countries barriers exist that prevent patients to access surgery. As people in the world live longer, the number of people with cataract is anticipated to grow. We found that Cataract is responsible for about 40-50% of all cases of blindness among the elderly in Nigeria, this finding data corresponds with the worldwide observation. The majority of the people who are blind from cataract live within the rural community. It is not an exaggeration to state that the best strategy for tackling cataract backlog and preventing blindness in the future lies in the community approach. In another study conducted on the ocular health, with respect to the rural dwellers in some communities in Nigeria, it was found that cataract was the most common eye problem encountered in 48% of the study population. Others were glaucoma (21.1%), allergic conjunctivitis (16.4%), refractive errors (12.4%), age related macular degeneration and corneal opacities (0.7%) each. (Adegbehingbe et al, 2007).

A reduction in cigarette smoking and avoiding ultraviolet light exposure may prevent or delay the development of cataract. Diabetes mellitus and high body mass index are identified as additional risk factors. The treatment of cataract is surgical and the procedure has been very successful in restoring sight. The opaque lens is removed and replaced with an artificial intraocular lens.

Our team documented that significant sight restoration rate from cataract surgery in a 5-year period was about 80%. Surgical outcome can be better with careful patient selection, meticulous surgery and appropriate surgical facilities. (Adeoye *et al*, 2003). However, in many remote parts of the developing world, people remain blind from cataract, due to a lack of access to eye care.

2. Onchocerciasis (River blindness)

Onchocerciasis is an insect-borne disease caused by a parasite *Onchocerca volvulus* transmitted by blackflies of the species

Simulium-damnosum. Onchocerciasis is often called "river blindness" because the blackfly that transmits the disease abounds in fertile riverside areas. *Onchocerca volvulus* is almost exclusively a parasite of man. Adult worms live in nodules in a human body where the female worms produce high numbers of first-stage larvae known as microfilariae. They migrate from the nodules to the sub-epidermal layer of the skin where they can be ingested by blackflies. They further develop in the body of the insect from which more people can be infected. Eye lesions in humans are caused by microfilariae. They can be found in all internal tissues of the eye except the lens where they cause eye inflammation, bleeding, and other complications that ultimately lead to blindness.

Onchocerciasis is a major cause of blindness in many African countries. As a public health problem, the geographic spread of the disease is most closely associated with riverine areas of the West and Central Africa, but it is also prevalent in Yemen and six countries in Latin America. Onchocerciasis has, in the past, greatly reduced the economic productivity in infected areas and left vast tracts of arable land abandoned. It is estimated that there are about half a million blind people have lost their eyesight due to onchocerciasis. Much progress has been made in fighting the disease in several countries through control of the blackfly;in addition, the disease can now also be treated with an annual dose of the drug I*vermectin (Mectizan®)*, which also relieves the severe skin itching caused by the filarial worms.

Although river blindness was put on the priority disease list of VISION 2020, global initiatives had already been taken for onchocerciasis control. Beginning in 1974, effective vector control was implemented in West Africa through the Onchocerciasis Control Programme (OCP). Since 1996, mass community-based Ivermectin treatment control African Programme for Onchocerciasis Control (APOC) in many African countries and the Onchocerciasis Elimination Programme in the Americas (OEPA) in the affected Latin American Countries has been successfully implemented. Onchocerchiasis control is not only an ongoing

success story of disease control, but also demonstrates the value of the synergy and cooperation that comes from working together in partnership, and the economic return and social development that results from investments made in a disease control programme.

3. Childhood blindness

Childhood blindness refers to a group of diseases and conditions occurring in childhood or early adolescence, which, if left untreated, will result in blindness or severe visual impairment that are likely to be untreatable later in life. The major causes of blindness in children vary widely from region to region, being largely determined by socioeconomic development, and the availability of primary health care and eye care services. In the industrialized countries, lesions of the optic nerve and higher visual pathways and retinopathy of prematurity predominate as the causes of blindness, while corneal scarring from measles, vitamin A deficiency, the use of harmful traditional eye remedies, *ophthalmia neonatorum*, and rubella cataract are the major causes in the developing countries. Other significant causes of childhood blindness ion all countries are congenital problems, such as cataract, glaucoma, and hereditary retinal dystrophies.

The prevalence of blindness in children varies according to socio-economic development and under-5 mortality rates (Gilbert *et al,* 2007). In low-income countries with high under-5 mortality rates, the prevalence may be as high as 1.5 per 1000 children, while in high-income countries with low under-5 mortality rates, the prevalence is around 0.3 per 1000 children. Using this correlation to estimate the prevalence of blindness in children, the number of blind children in the world is approximately 1.4 million. Approximately three-quarters of the world's blind children live in the poorest regions of Africa and Asia (WHO, 2002)

Prevention and treatment of childhood blindness is disease specific. For Vitamin A deficiency a diet rich in vitamins along with other nutrients, and also, at a very reasonable cost vitamin A supplements reduce child mortality by up to 34 per cent in areas

where Vitamin A deficiency is a public health problem. As vitamin A deficiency often manifests during an outbreak of measles, properly planned and implemented national vaccination programmes against measles have reduced the prevalence of eye complications. In industrialized countries, retinopathy of prematurity (ROP) is among the leading causes of childhood blindness, the incidence of which can be reduced through availability and affordability of screening and curative services. Early diagnosis and treatment of cataract and glaucoma can be beneficial, while low vision devices are helpful in children with severe visual impairment.

We reported a prevalence rate of severe visual impairment and blindness of 2% and 1.4% respectively, in a cross sectional study conducted among children attending a tertiary eye clinic in Ile-Ife. The causes were traumatic globe rupture, childhood cataract, corneal opacities, cortical blindness, ocular infections and retinal and optic nerve diseases. We discovered that majority of the cases were blind from preventable or treatable causes and advocated for prevention of trauma and genetic counseling. (Adegbehingbe et al, 2007).

Refractive errors and low vision

a. A refractive error is a very common eye disorder. It occurs when the eye cannot clearly focus the images from the outside world. The result of refractive errors is blurred vision, which is sometimes so severe that it causes visual impairment.

The four most common refractive errors types are:

- Myopia (nearsightedness): difficulty in seeing distant objects clearly
- Hyperopia (farsightedness): difficulty in seeing close objects clearly
- Astigmatism: distorted vision resulting from an irregularly curved cornea (the clear covering of the eyeball). This produces an effect whereby the eye can

sharply image a straight line lying only in one meridian).

- Presbyopia: this causes difficulty in reading or seeing at arm's length, it is linked to ageing and occurs almost universally.
- According to our study, presbyopia sets in at an earlier age, about 35-38 years among Nigerian young adults as compared to age 40-45years among Caucasians. Reasons for this as been attributed to prolong visual task and poor nutrition and stressed related lifestyle (Adegbehingbe *et al*, 2006).

Sometimes the degree or pattern of refractive errors may not be the same in both eyes and as such the two eyes may not focus accurately together, leading to suppression of vision in one eye with resultant misalignment of the visual axis and amblyopia. The two eyes most often work together to give a single bright vision, "if therefore your eyes are single great is thy light but if it be bad then the whole body is in darkness". Remember the eye is the ''Light of the body''.

WHO estimates that 153 million people worldwide live with visual impairment due to uncorrected refractive errors. This figure does not include the people living with uncorrected presbyopia, which is likely to be quite significant, according to some early evidence. Indeed, we have documented high rate of visual loss and blindness from various causes including refractive errors among students (Adegbehingbe et al, 2007), civil servants and children in Ile-Ife and environ (Adegbehingbe et al, 2008). Increased eye health education and provision of facilities for the correction of refractive errors and routine ophthalmic checkups for students, civil servants as means of enhancing their visual performance was recommended.

Refractive errors cannot be prevented, but they can be diagnosed by an eye examination and treated with corrective glasses, contact lenses or refractive surgery, often resulting in good visual function. If corrected in time by eye-care professionals, refractive errors do

not impede the full development of good visual function. Correction is provided in different forms according to the defect, the age of the person, the requirements in terms of work of activity performed.

As the coordinator of Prevention of blindness programme for my Hospital, we embarked on strategies to reducing the burden of visual impairment and blindness due to refractive error. I led the eye care team of Ife state Hospital to about 3 Primary and 6 secondary schools in Ife conducting sponsored free eye screening and providing over 300 free glasses to school children who could have developed refractive amblyopia with subsequent low vision or blindness.

b. Low Vision (LV)

Low Vision can be defined in two ways:

- Low vision is visual acuity less than 6/18 and equal to or better than 3/60 in the better eye with best correction (WHO).
- A person with low vision is someone who has impaired visual functioning even after treatment and/or standard refractive correction, and has a visual acuity of less than 6/18 to light perception, or a visual field less than 10 degrees from the point of fixation, but who uses, or is potentially able to use, vision for the planning and/or execution of a task for which vision is essential.

Recent studies have confirmed the existence of a large burden of uncorrected refractive errors causing low vision, although the interventions required are significantly cost effective, and have an important impact on economic development and quality of life.

5. Glaucoma

Glaucoma No Pain, No Symptom. Many Never Saw It Coming

Glaucoma has been nicknamed the "sneak thief of sight" because the loss of vision normally occurs gradually over a long period of

time without symptoms and is often only recognized when the disease is quite advanced. Once lost, the vision can never be recovered. Worldwide, it is the second leading cause of blindness and the most common cause of irreversible blindness and most especially in Nigeria. Glaucoma is a disease in which the optic nerve that subserves vision is progressively damaged due to increased pressure within the eye or because of blood flow related problems within the eye. The front of the eye is full of aqueous humor, a clear nourishing fluid that normally drains out through the capillaries. This fluid helps to maintain the pressure within the eye, intra-ocular pressure (IOP). Glaucoma is mostly caused by a blockage in the draining of this fluid, which can lead to extremely high pressure within the eye, causing damage to the optic nerve.

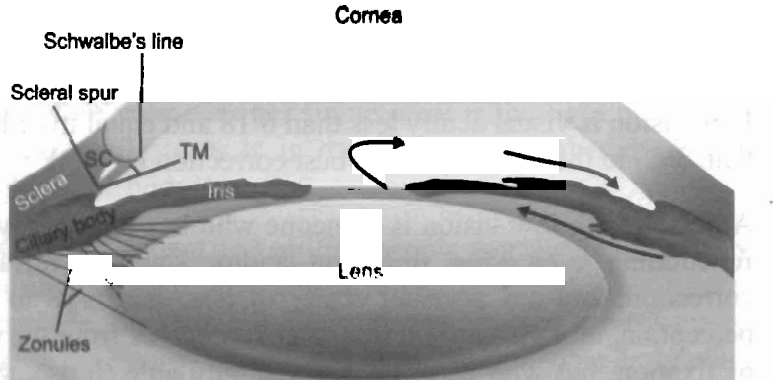

Figure 5. A diagram presenting the anatomic structure of the ocular drainage system for aqueous humor (Courtesy)

Glaucoma generally consists of a group of diseases that have as a common end-point a characteristic optic neuropathy which is determined by both structural change and functional deficit. The medical understanding of the nature of glaucoma has changed profoundly in the past few years and a precise comprehensive definition and diagnostic criteria are continuously evolving. There are several types of glaucoma, however, the two most common are primary open angle glaucoma (POAG), having a slow and

insidious onset, and angle closure glaucoma (ACG), which is less common and tends to be more acute.

The number of persons estimated to be blind as a result of primary glaucoma is about 4.5 million, accounting for slightly more than twelve per cent of all global blindness. Risk factors are those limited to the onset of disease and those associated with progressive worsening in already established disease. The primary risk factors that are linked to the individual and the onset of the disease are intra-ocular pressure, IOP level, age and genetic predisposition. The incidence of POAG rises with age and its progression is more frequent in people of African origin. ACG is the common form of glaucoma in people of Asian origin.

There is little known about primary prevention of glaucoma; however, there are effective methods of medical and surgical treatment if the disease is diagnosed in its early stage. Through appropriate treatment, sight may be maintained; otherwise the progression of the condition leads eventually to severe restriction of the visual field and irreversible blindness.

It has been found to contribute significantly to the burden of blindness in Nigeria and actually found to be the second most common cause of avoidable blindness in Nigeria. The majority of the patients with this irreversible blinding disease often present late due to its insidious asymptomatic nature. Studies of various modalities of treatment of this significant cause of blindness in Nigeria has been conducted and reported. (Adegbehingbe *et al*, 2008)

Risk factors for POAG include elevated intra ocular pressure (IOP), age, heredity/ ethnicity, high myopia, diabetes and elevated systolic blood pressure

Classification of Glaucoma

- Primary / Secondary Glaucoma
- Open angle glaucoma
- Closed angle glaucoma

- Normal tension glaucoma
- Congenital glaucoma

Secondary Glaucoma are those due to an injury, ocular or systemic diseases or drug complications.

Symptoms of POAG

POAG is usually symptomless and therefore often found incidental to a routine eye test. POAG results in a loss of peripheral vision, resulting in the individual bumping into objects occasionally. A reduced contrast sensitivity can sometimes occur, likewise ocular discomfort or heaviness.

Diagnosis

Glaucoma can be diagnosed by assessing the intraocular pressure (tonometry), visual field testing (perimetry), optic nerve head appearance (funduscopy) and anterior chamber angle examination (gonioscopy) and central corneal thickness (pachymetry). Retinal nerve fibre layer and optic nerve head assessment using Optical Coherence Tomography (OCT), optic nerve head polarimetry, scanning laser ophthalmoscopy, confocal scanning laser tomography and stereoscopic fundus photography are complimentary diagnostic investigations.

Intra-ocular pressure is the main modifiable risk factor and this also varies with the time of day (Diurnal variation of about > 2-6mmHg, heartbeat, respiration exercise (initial reduction), fluid intake (increase), systemic medications (diuretics or steroids), and topical medications. Others are age, caffeine (high), cannabis, alcohol (reduce), posture (supine high).

Figure 6. A fundus Photograph of a glaucomatous optic disc showing increased cup disc ratio and palor of the optic disc

Treatment

The modern goals of glaucoma management are to avoid glaucomatous damage, preserves visual field and total quality of life for patients with minimal side effects. This requires appropriate diagnostic techniques and follows up examinations and judicious selection of treatments for the individual patient. Although intraocular pressure is only one of the major risk factors for glaucoma, lowering it via various pharmaceuticals products, laser or surgical techniques is currently the mainstay of glaucoma treatment. Vascular flow and neurodegenerative theories of glaucomatous optic neuropathy have prompted studies on various neuroprotective therapeutic strategies including nutritional compounds some of which may be regarded by clinicians as safe for use now, while others are on trial.

Surgical procedure (trabeculectomy), which is widely performed relieves the high pressure within the eye by declogging the meshwork and creating a new path for the fluid to drain out from the eye. As part of the procedure a small collecting bag (bleb) is constructed out of tissue from the conjunctiva. This bag is placed under the upper eyelid and receives fluid from the new drainage

system, this then passes into the bloodstream through the capillaries. The new drainage pathways help in lowering the pressure within the eye. Though there are so many other surgical techniques, trabeculectomy procedure is the preferred line of surgical treatment for glaucoma in most places.

We conducted a review of the various treatment modalities of glaucoma patients receiving treatment at the Obafemi Awolowo University teaching Hospital Complex, Ile-Ife. It was documented that the success rate of trabeculectomy was similar to what obtains in the developed countries and that adjuvant treatment with 5-fluorouracil (5FU) was associated with higher success rate (Adegbehingbe *et al*, 2007).

However knowledge, attitude and self-care practices relating to glaucoma was very poor even among hospital workers and so we advocated for a more intensive eye health education and creation of awareness among hospital workers and the public at large (Adegbehingbe et al, 2008).

Also, one of the other major challenges in the treatment of glaucoma is the problem of availability, accessibility and affordability of the common first line medications. The need to make antiglaucoma drugs available for patients care at an affordable rate becomes a serious concern over the past few years.

In response to this challenge, I collaborated with fellow researchers in other parts of the country to research into locally available remedies of pharmacological significance. We made a very remarkable breakthrough in provision of more readily available and affordable therapeutic agents from a locally available herbal seed (*Garcinia Kola- orogbo*). This is the first indigenous antiglaucoma medication developed as a result of our clinical research. A randomized double masked multicentre active control prospective study evaluated the efficacy and safety of 0.5% aqueous ophthalmic solution of G. kola in newly diagnosed glaucoma patients. This preparation was found to be safe and have the same efficacy with gutt 0.5% Timolol in IOP reduction. The

use of this locally manufactured anti-glaucoma medication is increasing and well accepted among Nigerians (Adefule-Ositelu AO, 2010).

Laser Treatment for Glaucoma:

Other forms of treatment for glaucoma involves the use of a laser beams to destroy selected areas of the trabecular meshwork in order to increase the outflow of aqueous humor. The laser beam used can be either Argon or Nd:YAG Laser. Laser trabeculoplasty (LTP), is primarily used in the treatment of open angle glaucomas. Depending on the kind of laser beam used, the procedure is called Argon Trabeculoplasty (ALT) or Selective Laser Trabeculoplasty (SLT). Between the two, SLT is more specific in application with less collateral damage. It is also a repeatable procedure. For these reasons, SLT is increasingly being widely accepted as the laser therapy of choice for glaucoma treatment.

6. Diabetic retinopathy

Diabetic retinopathy is a major complication of diabetes that results from damage to the blood vessels of the light-sensitive innermost layer of the eye (retina).

Figure 7. A normal fundus and that showing diabetic retinopathy

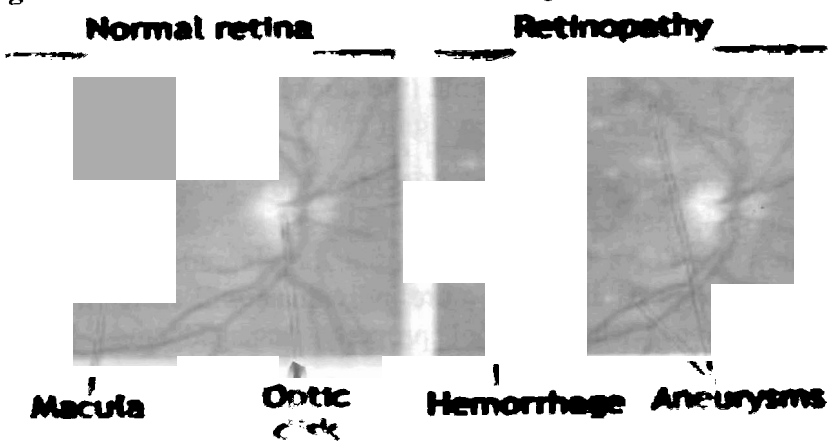

google.com.ng/books/about/Diabetic_Retinopathy.ht

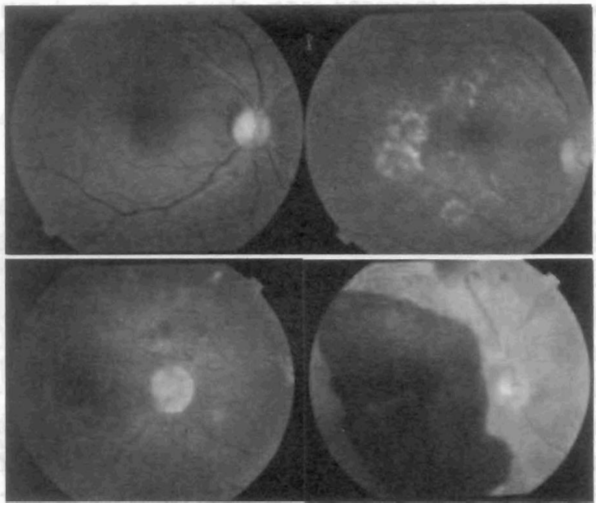

Figure 8. Diabetic Retinopathy (Courtesy: Eye Care Centre, OAUTHC)

Diabetic retinopathy is composed of a characteristic group of lesions found in the retina of individuals who have had diabetes mellitus for several years. The abnormalities that characterize diabetic retinopathy occur in predictable progression with minor variations in the order of their appearance. Diabetic retinopathy develops as a result of vascular changes in the retinal circulation.

In the early stages vascular occlusion and dilation occur. It progresses into a proliferative retinopathy with the growth of new blood vessels. Macular oedema (the thickening of the central part of the retina) can develop and significantly decrease visual acuity.

It is estimated that in the year 2002 diabetic retinopathy accounted for about 5 per cent of world blindness, representing almost 5 million blind. As the incidence of diabetes gradually increases, there is the possibility that more individuals will suffer from eye complications, which if not properly managed, may lead to permanent visual loss.

In the initial stages, diabetic retinopathy may cause no symptoms or present with only mild visual problems. The longer the duration

of diabetes, the more likely the possibility of developing diabetic retinopathy with eventual visual loss.

Despite the intimidating statistical burden of this disorder, research indicates that at least 90% of new cases of blindness could be reduced if there was proper and vigilant treatment and monitoring of the eyes.

Signs and symptoms of diabetic retinopathy

These include visible coloured Spots floating in the field of vision (floaters), blurred vision, visible dark streaks or a red film that blocks vision, poor night vision and sudden or progressive vision loss.

Diabetic retinopathy can be classified as Proliferative or non-proliferative (early or advanced). Non-proliferative diabetic retinopathy (NPDR) is the more common type. It can be described as mild, moderate or severe. In eyes with NPDR, the walls of the blood vessels in the retina weakens leading to leaking or oozing fluid and blood into the retina.

Proliferative diabetic retinopathy (PDR) is the most severe type of diabetic retinopathy. In eyes with PDR, abnormal blood vessels grow in the retina. Sometimes the new blood vessels grow or leak into the vitreous.

Risk factors

Risk factors for diabetic retinopathy include duration of diabetes, level of glycaemia, presence of high blood pressure, dependence on insulin, pregnancy, levels of selected serum lipids, smoking, nutritional and genetic factors. The control of glycemia decreases the risk of the incidence and the progression of the retinopathy. Medical interventions can decrease some of the risk to vision caused by diabetic retinopathy.

Early detection of diabetic retinopathy is the best way to prevent vision loss. Annual dilated eye exam by a specialist eye doctor is a must for those who have diabetes, even if the diabetic person does not have visual problems. They must also contact an eye doctor

right away if they experience a sudden decline in their vision or vision becomes blurry, spotty or hazy. During the exam, the eye doctor will look for evidence of abnormal blood vessels, swelling, blood or fatty deposits in the retina, damage to the nerve tissue, growth of new blood vessels and scar tissue, bleeding in the clear, jelly-like substance that fills the center of the eye vitreous) and retinal detachment.

Figure 9: Lecturer examining a patient's eye during a screening programme in a church.

Figure 10: Our Eye Care Team on Community Outreach

Treatment

Treatment for diabetic retinopathy depends on the type of diabetic retinopathy. Surgical intervention (vitrectomy), laser treatment and the use of anti-vascular endothelial growth factor has been the main modalities of treatment.

Laser photocoagulation used to be the main stay of management for some time. This could be in form of focal or scattered laser treatment. Focal Laser treatment (photocoagulation), can stop the leakage of blood and fluid in the eye. Scatter laser treatment. This laser treatment, also known as pan-retinal photocoagulation, can shrink the abnormal blood vessels.

The use of anti-vascular endothelial growth factor has been found to be very effective in controlling the vascular leakage and proliferation of new vessels in diabetic retinopathy while vitrectomy and surgical peeling of membranes have been very helpful in certain cases.

Prevention

The longer the duration of diabetes mellitus, the higher the risk of developing diabetic retinopathy, especially if diabetes is poorly controlled. There is a lot to be done to promote healthy eyes and vision in patients with diabetes mellitus. The patient should make a commitment to managing the disease. Oral diabetes medications or insulin must be used as directed.

Also routine monitoring of the blood sugar level is highly desirable. Patients may need to check and record their blood sugar level at least several times a day and even more regularly if patient was ill or under stress. Careful monitoring is the only way to make sure that the blood sugar level remains within your target range. The blood pressure and cholesterol must be kept under control. High blood pressure and high cholesterol increase the risk of vision loss in patients with diabetes. Eating healthy foods, exercising regularly and losing excess weight may prevent the risk of vision loss from diabetes. Patients must also quit smoking as

smoking increases the risk of various diabetes complications, including diabetic retinopathy.

7. Ocular Injury

Ocular (Eye) Injuries are common causes of blindness world-wide and most especially in the developing countries. It could be classified as physical (blunt or penetrating), chemical and radiation injuries.

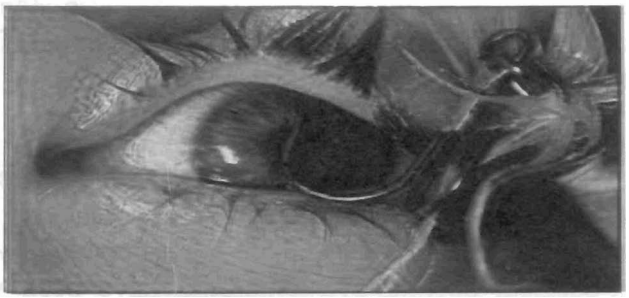

http://www.ncbi.nlm.nih.gov/pmc/articles/PMC3841540/

Figure 11: Here is a case of Fish hook injury to the eye (Penetrating Eye Injury)

Injury at workplaces, at home, at play and at schools is very common. In children, eye injuries can be prevented by keeping sharp objects away, by supervising their play and arranging the home to minimise home accidents. The use of injurious material by a parent or teacher while trying to inflict pain as a form of punishment (corporal punishment) has been found to be associated with uni-ocular or bilateral loss of vision especially among children. Prevention of such is highly desirable (Adegbehingbe *et al*,2007) .

Industrial workers and artisans e.g. welders should wear protective goggles especially when filing to prevent splinters from getting into the eye. When any chemical gets into the eyes the first thing that must be done is to copiously rinse the chemicals off with the closest source of water before seeking further care in a health centre or hospital. Ocular injury can result from a direct blow to

the face or as a result of head injury. Radiation injury may be insidious at onset though the effects may be devastating.

Approximately 2.4 million ocular and orbital injuries in the US per year, 20,000 to 68,000 of which are vision-threatening injuries and some 40,000 persons sustain significant vision loss each year. In Nigeria, eye injury was found to be responsible for bilateral blindness in 2.6- 7.9% of cases, also it's the 3rd commonest cause of monocular blindness according to several studies.

Industrial workers and artisans e.g. welders should wear protective goggles especially when filing to prevent splinters from getting into the eye. If any chemical gets into the eyes the first thing that must be done is to rinse the chemicals off with the closest source of water copiously before seeking further care in a health centre or hospital.

8. Age-related macular degeneration

The macula is the central part of retina which is responsible for central and sharp vision. It degenerates with advancement of age causing central vision loss. Many older people develop macular degeneration as part of the body's natural aging process. There are different kinds of macular problems, but the most common is age-related macular degeneration. Macular degeneration, **ARMD (Age-Related Macular Degeneration)**, is a condition affecting older people. It is the leading cause of vision loss and blindness aged 65 and older. It involves the loss of the person's central field of vision. It occurs when the macular (or central) retina develops degenerative lesions. It is thought that circulatory insufficiency, with reduction in the blood flow to the macular area, also plays a part. Several forms of AMD exist.

Two main types of Macular degeneration are common. The more common one is dry, or atrophic, macular degeneration (also called non-neovascular macular degeneration) presenting with drusens or the wet or neovascular type.

Globally, AMD ranks third as a cause of blindness after cataract and glaucoma. It is the primary cause of blindness in industrialized countries. The main risk factor is ageing. Other risk factors are tobacco consumption, genetic tendencies, the degree of pigmentation (with light coloured eyes being at higher risk), arterial hypertension, the ultraviolet rays, and consumption of a non-balanced diet. Most people who have macular degeneration have the dry form. This condition is caused by aging and thinning of the tissues of the macula. Macular degeneration usually begins when tiny yellow or white pieces of fatty protein called drusen form under the retina. Eventually, the macula may become thinner and stop working properly.

Dry Macular Degeneration
Yellowish spots (drusen) that form in the back of the eye or retina can be an early sign of "dry" macular degeneration occurs.

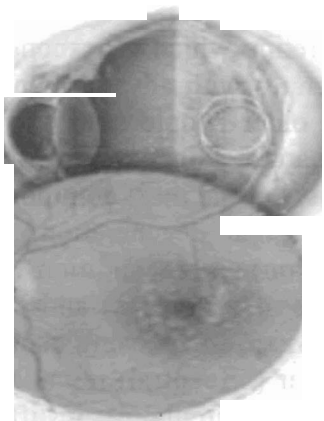

Wet Macular Degeneration
Abnormal blood vessels and leakage in the back of the eye (retina) affecting the macula which is the centre for fine focusing.

Figure 12: Age-related Macular Degeneration

Symptoms and Signs
Macular degeneration can lead to loss of vision, it often begins in just one eye, though the other eye may soon be affected. Many people are not aware that they have macular degeneration until they have a noticeable vision problem or until it is detected during an eye examination. Macular degeneration usually produces a slow, or rarely, sudden painless loss of vision. Early signs of

vision loss associated with AMD can include seeing shadowy areas in the central vision or experiencing unusually fuzzy or distorted vision.

DIAGNOSIS

With dry macular degeneration, vision loss is usually gradual. People who develop dry macular degeneration must carefully and constantly monitor their central vision. If an elderly person notice any changes in vision, he or she should contact the ophthalmologist to prevent the conversion of dry ARMD into the more damaging wet (exudative) macular degeneration.

The diagnosis of macular degeneration is made based on a thorough eye exam. Following diagnosis, additional tests may be performed to determine the location and extent of the disease.

Eye Examination

The doctor looks for presence of abnormalities in the macula, such as deposits called drusen. In addition, the appearance of the macula is important to sharp central vision — if the pigmentation is mottled or uneven, instead of its normal even reddish color, macular degeneration is usually the cause.

Amsler grid test

As a part of the eye examination, the physician may evaluate the patient's vision using a printed grid. If macular degeneration is present, the lines of the grid may seem faded, broken or distorted. By noting where the distortion occurs (usually near the center of the grid), the doctor can better determine the location and extent of macular damage.

Fluorescein angiography

This test is performed to determine the extent of the damage from macular degeneration. A special dye inject into a vein in the patient's arm, as the dye circulates through the bloodstream and eventually to the eye, the blood vessels in the retina stand out as bright yellow when observed with a special blue light. A camera takes flash photographs of the eye every few seconds for several

minutes, which help the doctor determine pigmentation changes or abnormal blood vessels.

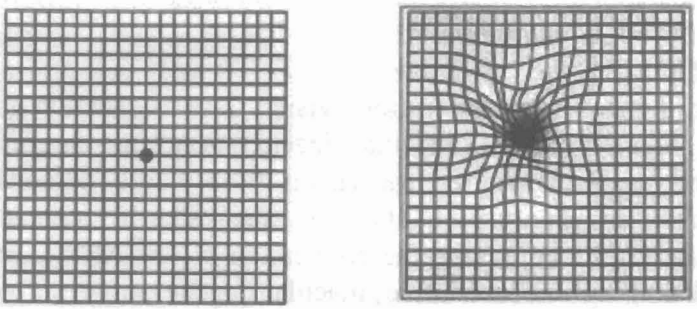

Normal Grid Distorted vision

Figure 13. Amsler grid appearance in normal and eye with ARMD

TREATMENT

There is at present no definitive treatment for ARMD. Palliative treatment which is able to retard the progress of the disease include the use of intra-vitreous drugs, lasers, dynamic phototherapy and sometimes surgery. The early beginning of rehabilitation for those with ARMD include psychological support, mobility and life skill training to enable the patient to enjoy a full life without limitations, as well as adaptation of the living and work places, and the use of special aids for reading and computer.

Many researchers and eye care practitioners believe that certain micro-nutrients such as zinc, lutein, zeaxanthin and vitamins A, C and E are helpful in reducing the risk for ARMD or in slowing down the progression of dry macular degeneration.

Anti-angiogenic substances often called anti-vascular endothelia growth factors (anti-VEGF) are very important treatment option for wet age related macular degeration. Drugs, such as pegaptanib sodium are injected into the affected eye to stop or slow down the blood vessels from growing, leaking and bleeding.

Laser treatment
Laser photocoagulation consists of using a high-energy laser beam to create small burns in areas of the retina with abnormal blood vessels to provoke a regression of such vessels.

Photodynamic Therapy
In this treatment, a drug called verteporfin is injected into the bloodstream. The drug concentrates in the abnormal blood vessels under the macula. Cold-laser light will be focused at the macula, which activates the drug which closes off of the abnormal vessels without damaging to the macula. Many other substances are been tested but they are all at experimental stages. At present, the available evidence points to the relevance of cessation of smoking in reducing the incidence of AMD.

9. Corneal opacities

The cornea is the clear membrane that covers the outside of the eye. Corneal opacities can be due to a wide variety of infectious and inflammatory eye diseases that can cause scarring of the cornea with eventual visual impairment. Significant scarring ultimately leads to functional vision loss.

Corneal blindness is a major cause of visual impairment (5.1%) after cataract, glaucoma and age-related macular degeneration (ARMD) globally. Trachoma is responsible for nearly 4.9 million blind individuals, mainly as a result of corneal scarring and vascularization. Ocular trauma and corneal ulcerations are significant causes of corneal blindness. They are often underreported but they are responsible for about 2.0 million new cases of unilateral blindness every year. In children, it is responsible for approximately 1.5 million cases out of 5 million cases of childhood visual impairment. Xerophthalmia accounts for 350,000 new cases per year; other infections which lead to corneal scarring in children include: neonate conjunctivitis, and rarer ocular infections like herpes and keratoconjuncticitis and toxic traditional medication are leading causes.

Onchocerciasis and leprosy are responsible for corneal opacities in some areas. Though the control of onchocerciasis and leprosy are public health success stories, these diseases are still significant causes of blindness, affecting approximately 250,000 individuals each. Eye medication administered by traditional healers such as juice from cassava or other leaves, breast milk, sugar and camphor water or human or cows urine have all been implicated as major risk factors in the current epidemic of corneal ulceration in developing countries (Adeoti, 2004).

Public health prevention programmes are the most cost-effective means of decreasing the global burden of corneal blindness Indeed, the only currently available curative treatment is surgery (keratoplasty/ cornea transplant). However, access to this surgery is very difficult, even in the developed countries, for lack of donors.

The findings from my research works confirmed that corneal opacities in Ile-Ife and environment are generally due to ocular trauma especially in cases of superficial foreign body, blast ocular injury and chemical injuries and ulcerative keratitis. (Adegbehingbe et al, 2004, 2005&2007)

10. Genetic eye diseases

Genetic eye diseases include a large number of ocular pathologies which have in common the transmission from parents to children through genetic inheritance. Some of these often cause visual impairment. Although there are no global statistics on the burden of visual impairment from genetic causes, it does seem that genetic eye pathology represents a significant percentage of the causes of blindness in industrialized countries. However, complications of genetic problems like sickle cell diseases, retinitis pigmentosa, hereditary maculopathies and ocular tumors (retinoblastoma) have been known to cause blindness and even death in some cases. The only current means of prevention of genetic eye pathology is genetic counseling.

The treatment of genetic eye disorders is largely experimental, with the exception of surgeries on the affected part of the globe, well-documented in certain cases. The best hopes for treatment, however, lie in the use of gene therapy, growth promotion therapies for degenerative diseases, and possibly the grafting of retinal cells.

When discussing issues of genetics, it is a known fact that many of the aforementioned eye diseases cluster in families, so one should become familiar with his family's history of eye disease because one may be at increased risk. Age-related eye diseases, including cataract, glaucoma, diabetic retinopathy and age-related macular degeneration are expected to dramatically increase from 28 million today (2016) to 43 million by the year 2020.

There are other less common avoidable causes of blindness and visual impairment especially in the developing. Among these are:

1. Tumours: Ocular tumors are common. The tumour could be benign or malignant. Benign lesions are commonly dermoid and epidermoid cyst and pterygium while childhood retinoblastoma and rhabdomyomas are the common malignant tumours. In adults the commonly seen malignant tumors are squamous cell carcinoma and Choroidal melanoma.

Figure 14: Advanced Retinoblastoma in a 3 year old child

2. Inflamations: Ocular inflammatory disorders can be infective or non-infective. The common non-infective causes are chalazion, orbital pseudo-tumors, uveitis and **retinitis** or chorioretinitis Allergic conjunctivitis is a very common form of ocular inflammation. It often presents with intense itching, redness and excessive tearing. Inflammation can be controlled but it could be exacerbated from time to time. Allergic conjunctivitis was the second most common reason for seeking treatment in the eye clinic at Obafemi Awolowo University teaching Hospital after refractive errors especially in the younger patients (Adegbehingbe *et al*, 2007)

3. Infections: Ocular Infection such as conjunctivitis, keratitis and keratoconjuncticitis. These can be treated early with antibiotic eye drops to prevent complications that can lead to blindness however delay in diagnosis and inappropriate treatment can cause blindness. There have been cases of topical application of urine rapidly leading to avoidable blindness from secondary infection from *Neiserria Gonorrhea.* We documented the common aetiologic organism responsible for conjunctivitis in Ile-Ife in our

research work with the aim of identifying the most effective antibiotics that can be used to treat such infections. (Adegbehingbe, et *al* 2005)

4. Vascular diseases: Hypertension, sickle cell anaemia, aneurysms and vascular insufficiency are known causes of visual impairment and blindness.

5. Other endocrine disorders as seen in thyroid eye disease, hypocalcaemia, hyoplyaemia and other metabolic imbalances has been associates with visual impairment and blindness.

Socio economic aspects of blindness and visual impairment

An analysis of the global distribution of blindness and visual impairment shows a disproportionately large prevalence in low-income developing countries. Cataract and trachoma are the greatest causes of avoidable blindness in those countries. Many individuals do not have access to prevention and eye care services. This severely deprives these regions of the benefits that can be realized by modern medical advancements.

Quality-Adjusted Life Years (QALYs)

The lack of economic development has been associated with the prevalence of visual impairment. Hence blindness prevention programmes must be concerned with not only the elimination of avoidable blindness but also with concurrent economic development. The costs of rehabilitation and care provided to the visually impaired are very enormous. Significant but less apparent however, are the indirect costs resulting from the loss of productivity.

The economic burden of visual impairment is commonly expressed as an additional yearly cost required for survival adjusted for the quality of life. Eye health programmes focusing on prevention of blindness and care of the visually impaired have elevated QALYs.

Disability-Adjusted Life Years (DALY)

The visually impaired person and his/her family face serious social challenges. Directly and indirectly visual impairment/ blindness interferes with many daily activities. In the case of adults, the possibilities for gainful employment are severely limited as is their participation in many activities. To this is often added a loss of social status and self esteem. The physical limitations and psychosocial implications of visual impairment cannot be measured in exact monetary terms. Nevertheless, it is clear that they diminish the quality of life not only for blind persons, but for their families as well.

A DALY method uses a derived measurement for calculating the losses and gains of life expectancy due to prevention, care and eventual rehabilitation in the case of visual impairment. The DALY combines in one measure the time lived with disability or poor health and the time lost due to premature mortality. One DALY can be thought of as one lost year of 'healthy' life and the burden of disease as a measurement of the gap between current health status and an ideal situation where everyone lives into old age free of disease and disability.

Lifestyle choices can directly affect eyes and vision.

1.Regular Eye Screening

All adults with no signs or risk factors for eye disease should get a baseline eye disease screening at age 40. This is the time when early signs of disease and changes in vision may start to occur. Based on the results of the initial screening, an ophthalmologist will prescribe the necessary intervals for follow-up exams. Anyone with symptoms or a family history of eye disease, diabetes or high blood pressure should see an ophthalmologist to determine the frequency of eye examination. This will ensure early diagnosis and intervention in the case of any serious eye conditions, such as glaucoma and AMD. These are more easily and successfully treated if diagnosed early. Left untreated, these diseases can cause serious vision loss and irreversible blindness.

2. Eye Protections (Goggles and Sunshades)

Eye protection with the use of ultraviolet (UV) light blocking sunglasses delays the development of cataract. Direct effect of UV light from sunlight hastens the development and progression of cataract. Also, sunglasses prevent retinal damage; protect the delicate eyelid skin from both wrinkles and skin cancer around the eye including cancerous and non-cancerous growths on the eye. One must ensure that the sunglasses block 100 percent of UV-A rays and UV-B rays.

It is also mandatory to wear proper eye protection to prevent eye injuries during sports such as hockey and baseball and home projects such as home repairs, gardening, and cleaning. For most repair projects and activities around the home, appropriate protective eyewear will be desirable. Sports eye protection should meet the specific requirements of that sport; these requirements are usually established and certified by the sport's governing body and/or the American Society for Testing and Materials (ASTM). Considering the roles of sun glasses in eye health preservation especially in the tropical weather, the misconception that wearing sunshade is for "posing" and fashion needs should be corrected.

Avoid Smoking

3. Tobacco smoking is directly linked to many adverse systemic and ocular health effects, including age-related macular degeneration (AMD). Studies show that current smokers and ex-smokers are more likely to develop AMD than people who have never smoked. Smokers are also at increased risk for developing cataracts.

4. Beware of fatigue

If you have eye strain from working at a computer or doing close work, you can follow the 20-20-20 rule: Look up from your work every 20 minutes at an object 20 feet away for twenty seconds. If eye fatigue persists, it can be a sign of several different conditions, such as dry eye, presbyopia, or spectacles with lenses that are not

properly centered. See an specialist to determine why you are having eye fatigue and to receive proper treatment.

5. Contact lens Care

The ophthalmologist's instructions regarding the care and use of contact lenses must be strictly followed. Abuse, such as sleeping in contact lenses that are not approved for overnight wear, using saliva or water as a wetting solution, using expired solutions, and using disposable contact lenses beyond their wear can result in corneal ulcers, severe pain and even vision loss. Contact lenses must be avoided in dry dusty environments.

6. Food, Vitamins and Eyes (Eat Right)

Vitamin deficiency can impair retinal function. The belief that eating carrots improves vision has some truth, but a variety of vegetables, especially leafy green ones, should be an important part of diet. Researchers have found people on diets with higher levels of vitamins C and E, zinc, lutein, zeaxanthin and omega-3 fatty acids are less likely to develop early and advanced AMD.

Also Iron deficiency anemia linked to thinner retinal nerve fiber layers. Investigators assessed the effect of iron deficiency anemia (IDA) on peripapillary retinal nerve fiber layer (RNFL) thickness in 102 female adults with IDA. Mean average RNFL as well as temporal, nasal and lower quadrant RNFLs were lower in the anemia group compared to controls (all $P<0.05$). Upper quadrant RNFLs were statistically similar to controls ($P = 0.114$). Additionally, RNFL thickness positively correlated with hemoglobin levels and various hematologic parameters. Further studies are ongoing to determine if RNFL thinning is associated with iron deficiency, anemic hypoxia or both.

The same diet that helps our hearts is probably also good for our eyes. A diet low in fat and rich in fruits, vegetables and whole grains can pay benefits not only to the heart but also to the eyes. The connection isn't surprising: our eyes rely on tiny arteries for

oxygen and nutrients, just as the heart relies on much larger arteries. Keeping those arteries healthy will help our eyes.

Some foods stand out as particularly helpful for eye health. Christopher Hammond, M.D., FRCOphth, Professor of ophthalmology at King's College, London opined that "While we cannot totally avoid developing cataracts, we may be able to delay their onset and keep them from worsening significantly by eating a diet rich in vitamin C," The researchers noted that the findings only pertain to vitamins consumed through food and not supplements. Vitamin C is a powerful antioxidant. The fluid inside the eyeball is normally high in a compound similar to vitamin C, which helps prevent oxidation that results in a clouded lens. Scientists believe more vitamin C in the diet may increase the amount present around the lens, providing extra protection. In other to maintain healthy eyes, we should ensure the following form part of our regular diet.

a. **Leafy green vegetables:** These are rich in anti-oxidant including lutein and zeaxanthin. These two nutrients found in the healthy eyes are believed to lower the risk for developing age related macular degeneration (ARMD) and cataract. One large study showed that women who had diets high in lutein were 23 percent less likely to develop cataracts than women whose diets were low in this nutrient. Other dark leafy green vegetables, like spinach, Ugwu, lettuce, and turnip greens, also contain significant amounts of lutein and zeaxanthin. Eggs are also a good source of these nutrients, as are broccoli, peas and corn.
b. **Orange:** Oranges and all of their citrus cousins — grapefruit, tangerines, and lemons — are high in vitamin C, an antioxidant that is critical to eye health. Scientists have found that your eyes need relatively high levels of vitamin C to function properly, and antioxidants can prevent or at least delay cataracts and AMD. Lots of other foods offer benefits similar to oranges, including peaches, red peppers, tomatoes and strawberries.

c. **Black-eyed peas.** Legumes of all kinds, including black-eyed peas, kidney beans, lima beans, and peanuts contain zinc, an essential trace mineral that is found in high concentration in the eyes. Zinc may help protect eyes from the damaging effects of light. Other foods high in zinc include oysters, lean red meat, poultry and fortified cereals.

d. **Carrots:** Carrots are high in beta-carotene, a nutrient that helps with night vision, as are other orange-colored fruits and vegetables like sweet potatoes, apricots and cantaloupe. Making them a part of a colorful diet can help keep the eyes healthy.

e. **Salmon:** Some studies suggest that diets rich in omega-3 fatty acid from cold-water fish like salmon, tuna, sardines and halibut reduce the risk of developing eye disease later in life. A 2010 study from Johns Hopkins found that people who had a diet high in omega-3 fatty acid were much less likely to develop AMD.

Know Your Eye Care Provider

When someone goes to get the eyes checked, there are a variety of eye care providers one might see; all play an important role in providing eye care services to consumers. However, each have different levels of training and expertise. Make sure you are seeing the right provider for your condition or treatment.

Ophthalmologist

Ophthalmologists are medical doctors who had completed a 6-7 year training in medical schools but later specialize in eye care after a period of at least another 6 years of postgraduate residency training. They diagnose and treat eye disease and associated general medical problem. Ophthalmologists are eye medical doctors specially trained to provide the full spectrum of eye care from prescribing glasses and contact lenses to complex and delicate eye surgery. They do a comprehensive eye test and can identify systemic problems during the course of managing eye problem and give immediate treatment and/or appropriate referral of such cases.

Optometrist/ Prescribing Opticians

Optometrists / prescribing optician are university graduate who are trained to measure and correct refractive errors with glasses/ contact lenses. These are Physicists who are awarded doctor of Optometry at the end of their university first degree training in Optometry (a field of Physics). After screening patients for need of glasses or contact lenses, they refer patients to Eye medical doctor (Ophthalmologist) for complete eye evaluation and provision of appropriate care for their systemic and eye diseases. They are referred to as Prescribing Opticians in some countries.

Dispensing Opticians

Dispensing Opticians are trained to dispense prescriptions for glasses and contact lenses. They are technicians who are supposed to have undergone some training in how to cut and glaze glasses. They are not necessarily university graduate but some have a diploma from the technical schools.

Ophthalmic Nurses

Ophthalmic Nurses are registered nurses who had specialised training in working with Ophthalmologist. They assist the eye medical doctors in patient's management. They give health talks, assist with primary eye care and during eye surgery and in pre/post operative care of patients.

Community Eye Health Extension Workers (CHEW) are graduates of school of health technology. They advocate for Primary Eye Health and assist in prompt referral of patients with Eye diseases

The Eye Health team is not complete without the administrators, pharmacist, medical record officers, the cash officers and the facility house keepers and community field workers.

Closely knitted collaboration and harmony between the various groups of people involved in the management of patients with eye diseases are necessary to be able to prevent every form of preventable blindness. However, poor recognition of limit of practice of any of the health care management team can lead to serious consequences which eventually lead to blindness.

Increase in eye health education for medical personnel, non-medical personnel and general public is the only means of reducing the burden of blindness and attaining VISION 2020 (Right to Sight)

Conclusion

Mr Vice Chancellor sir, apart from the above mentioned contribution to knowledge, during the course of my carrier as an Ophthalmologist. I have mentored and trained about 14 five star Consultants Ophthalmologists. Some of them are already in professorial cadre in their respective departments of Ophthalmology, medical directors, and heads of departments in their various academic or health institutions. I have also supervised and assessed more than 20 research projects in Ophthalmology and related disciplines and I am currently supervising about four theses in this academic year.

I have been an examiner at both the National Postgraduate Medical College and West African College of Surgeons for over the past eight years. I have been a member of the Faculty Board of Ophthalmology of the National Postgraduate Medical College of Nigeria for a number of times. I was the head of the team that revised the curriculum for the diploma programme in Ophthalmology in West Africa.

I have been a member of Oxford Ophthalmologic Congress and an International member of American Academy of Ophthalmology since 2005. I have presented several articles in several internal conferences including World Ophthalmologic conference. I have published about 52 original articles in reputable international

journals. The community outreach programme which I championed over the past 15 years have been passionately pursued by all my colleagues, resident doctors and all other members of the Eye care team in Ile-Ife.

Through our research work, we have been able to document a high prevalence of blindness and severe visual impairment among people in various groups and settings in Nigeria. Significant differences exist between different ethnic group and geopolitical zones. Therefore emphasis should be on providing eye care services across Nigeria. This means that eye health planning at the regional level is necessary. .

An increased in the availability of eye care services and an increase in awareness in the general population about solutions to the problems related to visual impairment has had a positive impact. However, the level of awareness and accessibility to appropriate eye care services (surgery, refraction devices, etc.) are strictly limited in the developing countries. So if our earnest plea is "That I May See", how can we then preserve our vision?

To avoid blindness or visual impairment there is a need for early consultation with an eye care specialist (Early diagnosis, prompt and appropriate treatment). We must all endeavour to have a regular eye check ups, even if you don't have any serious complaint and avoid self medication (Systemic or topical), some of these drugs have ocular complications.

Efforts must be made to regularly take a balanced diet (rich in vitamins).

We must avoid self medication and the instillation of breast milk, sugar or camphor water, human urine, juice from plants/ leaves or battery water and other forms of traditional eye care practices.

Eating at least one seed of *Orogbo* per day will not only enable us to enjoy good health but it will surely help to preserve our vision.

Mr. Vice Chancellor Sir, the whole essence of my pursuit of a career in ophthalmology is to fulfill the request of that blind man "That I May See" in all persons who have the same demand from their physician.

I hereby offer my immense gratitude to my parents, siblings, in-laws, friends, all my teachers from basic school through my postgraduate training including my spiritual teachers, all my colleagues at various stages of my education, all members of my department, the staff and management of Obafemi Awolowo University Teaching Hospitals complex, the entire university and general community who have contributed in one way or the other to mold me into who I am today. Thank you all for your support, care and love.

I am eternally grateful to my children for quietly cooperating with me during those years of residency training and research work in my academic pursuit without whose love and understanding there will not be a day like today.

I once again declare before all men that God has blessed me with a friend who has been a father, companion, mentor and a brother to me for over the past 30 years and 25 years of our marriage. He encouraged and supported me all the way through and insisted I should take a day for my inaugural lecture to mark our wedding anniversary this month. Thank you darling. God bless you forever.

To the Lord eternal, the merciful, gracious and my redeemer I give all the honour, adoration and glory for all He has done for me.

Mr Vice Chancellor Sir, distinguished ladies and gentlemen, I thank you all for coming and for listening with rapt attention.

God bless you all.

REFERENCES

Abdull MM, Sivasubramaniam S, Murthy GV, Gilbert C, Abubakar T, Ezelum C, Rabiu MM; Nigeria National Blindness and Visual Impairment Study Group. Causes of blindness and visual impairment in Nigeria: the Nigeria national blindness and visual impairment survey. *Investigative Ophthalmology and Vision Science*. 2009 Sep; 50(9):4114-20.

Abiose A, Murdoch I, Babalola O, et al. Distribution and aetiology of blindness and visual impairment in mesoendemic onchocercal communities, Kaduna State, Nigeria. *British Journal of Ophthalmology*. 1994; 78:8–13.

Adegbehingbe BO, Williams C, Easty DL. Driving, glaucoma, and the Law. Patients need more information. *British Medical Journal*. 1995 ; 310 (6): 56.

Adegbehingbe BO, Majekodunmi AA, Akinsola FB, Soetan EO. Pattern of Refractive Errors at Obafemi Awolowo University Teaching Hospital, Ile-Ife. Nigeria. *Nigerian Journal of Ophthalmology. 2003;* 11:76-79.

Adegbehingbe BO, Oluwadiya KS, Adegbehingbe OO. Motorcycle Associated Ocular Injuries in Ile-Ife, Nigeria. *African Journal of Trauma*. 2004; 2 (1): 35-39.

Adegbehingbe BO, Adeoye AO, Onakpoya OH. Refractive Errors in Childhood. *Nigerian Journal of Surgical Sciences*. 2005; 15 (1): 19-25

Adegbehingbe BO, Onipede AO. Conjunctivitis as Seen in Ile-Ife. Nigeria. *Nigerian Journal of Ophthalmology*. 2005; 13 (1): 21-26.

Adegbehingbe BO, Komolafe EO, Komolafe MA, Olateju OS, Adeoye AO, Amusa YB et al. Epidemiology of Non-

glaucomatous Optic Atrophy in a Nigerian teaching Hospital. *Nigerian Journal of Surgery*. 2005; 11(1): 31-35.

Adegbehingbe BO, Olasode AO. Value of Ophthalmic features as means of diagnosis of HIV/AIDS infection. *Annals of Saudi Medicine*. 2005; 25(5) 435-436.

Adegbehingbe BO, Olabanji JK, Adeoye AO. Isolated bilateral upper coloboma—a case report. *Nigerian Journal of Medicine*. 2005; 14 (2): 224-6

Adegehingbe BO, Onakpoya OH. Intra-operative 5fu in Glaucoma Surgery. A Nigerian Teaching hospital Experience. *Middle East African Journal of Ophthalmology*. 2008; 15 (2): 57-60

Adegbehingbe BO, Ajite KO, Adegbehingbe OO. Incidence of Ocular congenital anomalies in Nigerian teaching Hospital. *Orient Journal of Medicine*. 2005; 17(3-4): 31-36

Adegbehingbe BO, Majengbasan T .A review of trabeculectomies at a Nigerian teaching hospital. *Ghana Medical Journal* 2007; 41(4): 176-180

Adegbehingbe BO Blindness from bilateral bullous retinal detachment: tragedy of a Nigerian family. *African Health Sciences.2008*; 8(1): 51-54

Adegbehingbe BO, Taiwo OA. Prevalence and pattern of childhood blindness in a resource limited teaching hospital in Nigeria. *East African Journal of Ophthalmology.2007;* 7: 43-47

Adegbehingbe BO, Oladehinde MK, Majemgbasan TO, Onakpoya OH, Osagiede EO. Screening of Adolescents for eye diseases in Nigerian high schools. *Ghana Medical Journal*; 2005 39(4): 138-142

Adegbehingbe BO, Soetan EO. Risk factors for early presbyopia in Nigerians. *Nigerian Journal of Surgical Sciences. 2006*; 16(1): 7-11.

Adegbehingbe BO, Olasode OA. Ocular disease in HIV AIDS. *Nigerian Journal of Surgical Sciences. 2006*; 16(2): 47-5

Adegbehingbe BO, Adeoye AO, Adewara BA. Ocular Co-morbidity with refractive errors in Nigeria. *Nigerian Journal of Ophthalmology 2011*; 19:19-24

Adegbehingbe BO, Onakoya AO, Adio AO, Fadamiro CO, Badmus SA, Olorundare O, Ogundipe BO. (2012) Challenges of Corneal transplant. *Nigerian Journal of Health Sciences*.2012; 8: 14-17.

Adegbehingbe BO, Ihemedu C. Prevalence of undiagnosed glaucoma among workers in a Nigerian Hospital. *Nigerian Journal of Health Sciences*; 2013: 10-13

Adegbehingbe BO, Fajemilehin B R, Ojofeitimi E O, Bisiriyu LA. Blindness and visual Impairment among the elderly in Ife-Ijesha Zone of Osun State, Nigeria. *Indian Journal of Ophthalmology.2006*; 54(1): 59-62

Adegbehingbe BO, Oladehinde MK, Majengbasan TO, Onakpoya HO, Osagiede EO. Ocular morbidity in Secondary school students in Ile-Ife, Osun state, Nigeria. *Nigerian Journal of Ophthalmology.2006*; 14 (2): 60-64

Adegbehingbe BO, Ajite KS. Corporal punishment-related ocular injuries in Nigerian Children. *Journal of Indian Association of Pediatric Surgeons. 2007*; 12 (2): 76-79

Adegbehingbe BO, Majengbasan T A. Ocular health status of rural dwellers in south- western Nigeria. *Australian Journal of Rural Health. 2007*; 15: 269-272.

Adegbehingbe OO, Owa JA, Kuti O, Olabanji JK, **Adegbehingbe BO**, Oginni LM. Predictive factors for birth injuries in Southwestern Nigeria. *African Journal of Surgery. 2007*; 4 (1): 20-25

Adegbehingbe BO, Soetan EO, Adeoye AO. Case report: Intraocular Cysticercosis. *West African Journal of Medicine. 2003*; 22(4): 354-355.

Adegbehingbe OO, **Adegbehingbe BO**, Olorunnisola O.A, Onakpoya OH. Ophthofall: A risk factor for falls and fractures among Orthopaedic in-patients in Nigeria *The Internet Journal of Ophthalmology and Visual Science.* http://www. ispub.com.2008; Vol 5.

Adegbehingbe OO, Adetiloye VA, **Adegbehingbe BO**, Adeolu A.A, Famurewa C.A. Evaluation of CT scanned multiple injured in peace time and Ile-Ife Modakeke Communal War. *The Internet Journal of Rescue and Disaster Medicine.* http://www.ispub.com.2009; Vol. 17 (2)

Adegbehingbe BO, Bisiriyu LA. Knowledge, attitudes and self Care practices associated with glaucoma among hospital workers in Ile-Ife, Osun state, *Tanzanian Journal of Health Research.2008*; 10 (4): 240-5

Adegbehingbe BO, Adegbehingbe OO, Tanimowo O. Clinical features and visual outcome of blast ocular injuries in South Western Nigeria. *Nigerian Journal of Health Sciences. 2010*; 10 (2): 13-16

Adegbehingbe BO, Ouertani AM. Confocal Scanning laser Tomography of the optic nerve head of glaucoma patients:

Inter-correlation of disc parameters. *Ghana Medical Journal*.2009; 43(4): 150-6

Adefule-Ositelu AO, **Adegbehingbe BO**, Adefule A.K, Adegbehingbe OO, Samaila E, Oladigbolu K. Efficacy of Garcinia Kola 0.5% Aqueous Eye Drops in patients with primary Open-Angle Glaucoma or Ocular Hypertension. *Middle East African Journal of Ophthalmology. 2010*; 17(1): 88-93

Adefule- Ositelu AO, Aribaba OT, **Adegbehingbe BO**, Adefule A.K, Samaila AA, Oladigbolu K. Pupillary Changes Among Nigerian Adults Following The Instillation Of Garcinia Kola Nut Extract: Multicentric Studies. *The Nigerian Postgraduate Medical Journal. 2008*; 15 (3): 152-156.

Adeolu AA, Adisa AO, Ayoola OO, Olateju SO, Ibitoye BO, **Adegbehingbe BO**, Komolafe EO. Neglected massive intracerebral abscess: an unusual cause of bilateral visual loss; *Nigeria Postgraduate Medical Journal 2008*; 15(1): 52-4

Adeoti CO. Prevalence and causes of blindness in a tropical African population. *West African Journal of Medicine*. 2004; 23: 249–252.

Adeoye AO, **Adegbehingbe BO**, Olateju SO, Oladehinde KM. Audit of Cataract Surgery at Ile-Ife. *Nigerian Journal of Surgical Sciences, 2003*; 13 (2): 66-69.

Ajite KO, Adeoye AO, **Adegbehingbe BO**, Olateju SO, Onakpoya OH. Pattern of Visual Impairment and Blindness in a Nigerian Prison. *International Journal of Prisoner Health. 2010*; 6 (1): 41-4

Amusa YB, Akinpelu OV, Komolafe EO, Adeolu AA, Komolafe MA, Olateju SO, **Adegbehingbe BO**, Famurewa OC, Ashaleye CM . Aetiology of vertigo in a Nigerian Tertiary Health Facility, A Multidisciplinary Approach. *Nigerian Journal of Otorhinolaryngology 2005*; 2 (2: 54-59).

Amusa YB, Adediran IA, Akinpelu VO, Famurewa OC, Olateju SO, **Adegbehingbe BO**, Komolafe EO, Faponle AF, Olasode BJ. Burkitt's Lymphoma of the Head and Neck Region in a Nigerian tertiary Hospital. *West African Journal of Medicine*. 2005; 24(2):139-142.

Dineen B, Gilbert CE, Rabiu MM, *et al*. The Nigeria National Blindness and Visual Impairment Survey: rationale, objectives and detailed methodology. *BMC Ophthalmology*. 2008; 8: 17.

Entekume G, Patel J, Sivasubramaniam S, Gilbert CE, Ezelum CC, Murthy GV, Rabiu MM; for the Nigeria National Blindness and Visual Impairment Study Group. Prevalence, causes, and risk factors for functional low vision in Nigeria: results from the National Survey of Blindness and Visual Impairment. *Investigative Ophthalmology and Vision Science*. 2011 Aug 24; 52(9): 6714-6719.

Fajemilehin BR, Ojofeitimi EO, **Adegbehingbe BO**, Asa SS, Bamiwuye SG, Owolabi OO. Nutritional and Health Status in an Elderly population in Nigerian. *African Journal of Nursing and Midwifery.2005;* 6 (1): 17-22.

Goh PP, Abqariyah Y, Pokharel GP, Ellwein LB. Refractive error and visual impairment in school-age children in Gombak District, Malaysia. *Ophthalmology* 2005; 112: 678-685

Naidoo KS, Bourne RR, Flaxman SR, Jonas JB, Keeffe J *et al*. Global Vision Impairment and Blindness Due to Uncorrected Refractive Error, 1990-2010.

Optometric Vision Science. 2016 Mar; 93(3): 227-34.

Oginni FO, Ugbokwo VI, Ogundipe O, **Adegbehingbe BO**. Motor-cycle Related Maxillofacial Injuries amongst Nigerian Intracity Road Users. *Journal of Oral and Maxillofacial Surgery. 2006*; 64(1): 56-62.

Ojofeitimi EO, Adedigba MA, Ogunbodede EO, Fajemilehin BR, **Adegbehingbe BO**. Oral Health and the elderly in Nigeria: A case for oral health promotion. *Gerodontology. 2007*; 24: 231-234

Oladehinde MK, Adeoye AO, **Adegbehingbe BO**, Onakoya AO. Visual functions of commercial drivers in relation to road accidents in Nigeria. *Indian Journal of Occupational and Environmental Medicine. 2007*; 11 (2) 71-75.

Oladehinde MK, **Adegbehingbe BO**, Adeoye AO, Onakpoya AO. Central nervous system stimulants: effects on visual functions and occurrence of road traffic accidents. *EUVision. 2007*; 4: 11-17

Oluleye TS, Ajaiyeoba AI, Akinwale MO, Olusanya BA. Causes of blindness in Southwestern Nigeria: a general hospital clinic study. *European Journal Ophthalmology*. 2006;16: 604–607.

Onakpoya OH, Adeoye AO, Akinsola FB, **Adegbehingbe BO**. (2007). Prevalence of blindness and visual impairment in Atakumosa West Local Government Area of Southwestern Nigeria. *Tanzania Health Research Bulletin.2007*; 9(2): 126-131

Onakpoya OH, Komolafe EO,Akintomide F, Ajite K, Komolafe MA, Adeolu AA, Olateju SO, Adeoye AO, **Adegbehingbe BO**: Ophthalmic Manifestation in patients with intracranial tumours. *African Journal of Neurological Sciences*. 2009; 28:334-338.

Onakpova OH, **Adegbehingbe BO**, Omotoye OJ, Adeoye. Causes of blindness in a special education school._*West African Journal of Medicine* 2011; 30(1):47-50.

Rabiu MM. Cataract blindness and barriers to uptake of cataract surgery in a rural community of northern Nigeria. *British Journal of Ophthalmology*. 2001;85:776–780.

Rabiu MM, Kyari F, Ezelum C, Elhassan E, Sanda S, Murthy GV *et al*. Review of the publications of the Nigeria national blindness survey: methodology, prevalence, causes of blindness and visual impairment and outcome of cataract surgery. *Annals of African Medicine*. 2012 Jul-Sep; 11(3): 125-30.

Stevens GA, White RA, Flaxman SR, Price H, Jonas JB, Keeffe J, Bourne RR; Vision Loss Expert Group. Global prevalence of vision impairment and blindness: magnitude and temporal trends, 1990-2010. *Ophthalmology*. 2013; 120 (12): 2377-84.

Taiwo OA, Beki-bele CO, Adeoye AO, **Adegbehingbe BO**, Onakpoya OH, Olateju SO, Ajite KO. (2014). Prevalence and pattern of eye disorders among commercial motorcycle riders in Ile-Ife, Osun State. *The Nigerian Postgraduate Medical Journal*; 21(3): 255-261

Umeh RE, Chijioke CP, Okonkwo PO. Eye disease in an onchocerciasis-endemic area of the forest-savannah mosaic region of Nigeria. *Bulletin of the World Health Organization*. 1996; 74: 95–100.

World Health Organization. VISION2020: The Right to Sight. Global Initiative for the Elimination of Avoidable Blindness: Action Plan 2006–2011. World Health Organization, Geneva, Switzerland; 2007; 1–97.

World Health Organization. Coding Instructions for the WHO/PBL Eye Examination Record (Version III). Geneva: WHO; 1988 WHO document PBL/88.1